

COVID vs Cancer: Impact on Head and Neck Oncology

Management of the Difficult Airway in the COVID-19 Pandemic: An Illustrative Complex Head and Neck Case Scenario

Christopher Rassekh, Et Al.

Cite as: Christopher Rassekh et al. Management of the Difficult Airway in the COVID-19 Pandemic: An Illustrative Complex Head and Neck Case Scenario. *Authorea*. April 02, 2020.

This is a preprint and has not been peer reviewed. Data may be preliminary.

Abstract

Background: This case highlights challenges in the assessment and management of the “difficult airway” patient in the SARS-CoV-2 (COVID-19) pandemic era. **Methods:** A 60-year-old male with history of recent TORS resection, free flap reconstruction and tracheostomy for p16+ squamous cell carcinoma presented with stridor and dyspnea one month after decannulation. Careful planning by a multidisciplinary team allowed for appropriate staffing and personal protective equipment, preparations for emergency airway management, evaluation via nasopharyngolaryngoscopy, and COVID testing. The patient was found to be COVID negative and underwent imaging which revealed new pulmonary nodules and a tracheal lesion. **Results:** The patient was safely transorally intubated in the operating room. The tracheal lesion was removed endoscopically and tracheostomy was avoided. **Conclusions:** This case highlights the importance of careful and collaborative decision making for the management of head and neck cancer and other “difficult airway” patients during the COVID-19 epidemic.

Full author list

Christopher H. Rassekh MD 1 , Carolyn M. Jenks MD 1 , E. Andrew Ochroch MD 2 , Jennifer E. Douglas MD 1 , Bert W. O’Malley, Jr. MD 1 , Gregory S. Weinstein MD 1

1 Department of Otorhinolaryngology, Hospital of the University of Pennsylvania

2 Department of Anesthesiology and Critical Care, Hospital of the University of Pennsylvania

INTRODUCTION

The following case highlights new challenges and complexities in the assessment and management of the “difficult airway” patient in the COVID-19 (SARS CoV-2) pandemic era.

CASE REPORT

A 60-year-old male presented to the emergency department (ED) with progressive stridor. His history was notable for radical tonsillectomy, neck dissection, radial forearm free flap and tracheostomy for a locally and regionally advanced p16+ squamous cell carcinoma (SCCA) approximately two months earlier. The patient’s tracheostomy had been removed one month prior to presentation, and he had just begun postoperative chemoradiation. The patient was known to our head and neck team having had his surgery in our division.

The otolaryngology consult resident (JED) was called for urgent airway evaluation. As a result of new residency policies, the junior resident consulted with the attending consult faculty (CHR) prior to seeing

the patient, who determined a need for a conference call with the junior and senior resident (CMJ). We developed a plan for definite hospital admission and likely nasopharyngolaryngoscopy (NPL). Complicating this was the fact that the patient was considered a "PUI" (patient under investigation/rule out COVID-19). Although the patient had stridor and positional dyspnea (when lying down), he was reportedly not having any oxygen requirement and was otherwise stable.

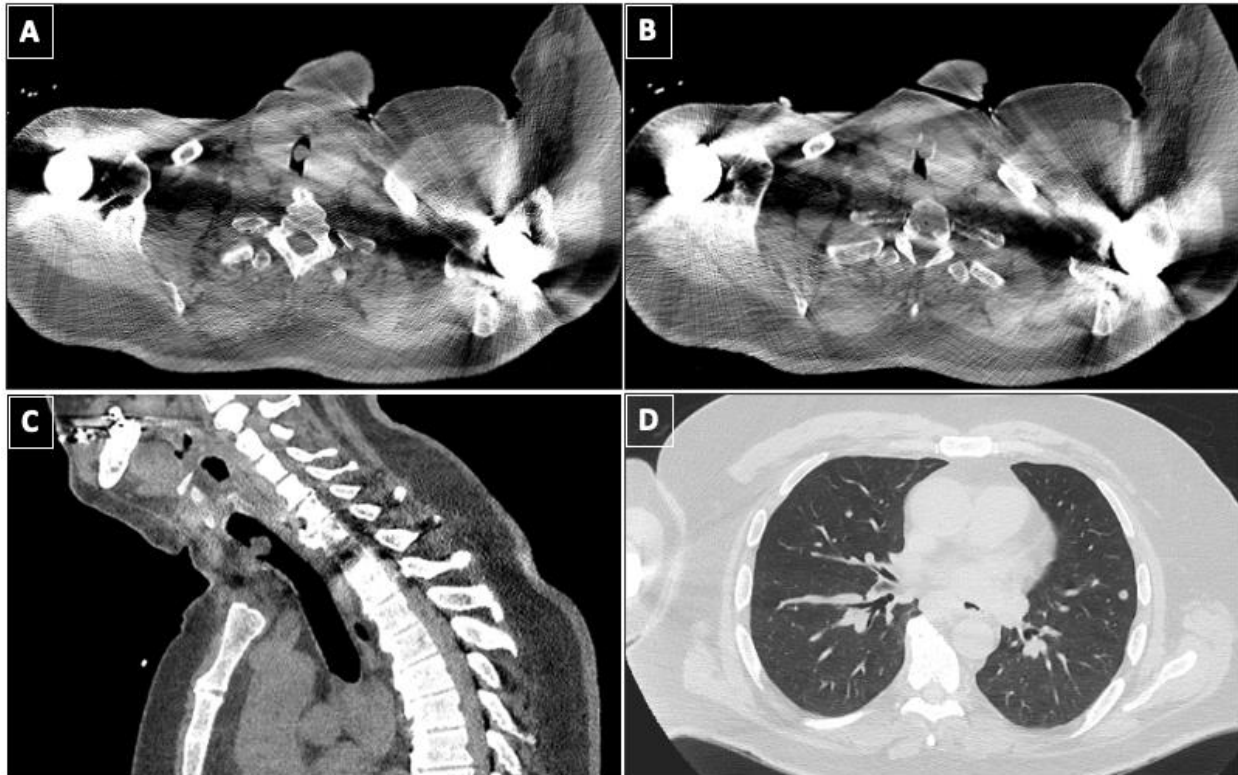
A plan was made for the consult team to arrive at the ED together, assess the patient, and discuss with the ED attending prior to performing any procedure. We realized that in the setting of a potential COVID infection, team members were at risk of exposure even during a standard head and neck exam and that any airway procedure including NPL would ideally require full personal protective equipment (PPE). The added risks and resources needed for airway evaluation and management in a PUI prompted us to activate the Airway Rapid Response (ARR) team for a more comprehensive team huddle. Airway Rapid Response mobilized the key personnel and equipment that might be needed if the situation deteriorated, and it allowed us to discuss the consequences of the options available with all key personnel. Notably, in the COVID era, team members attempted to maintain six feet of distance between each other during the huddle.

Ultimately, it was determined that the consult faculty should don full PPE (powered air-purifying respirator [PAPR], gown, and gloves) and enter the room to do an airway assessment while the rest of the airway team prepared to don PPE in the event they were also needed. Upon entry into the room, the patient, who was wearing a surgical mask, was extremely anxious, had loud stridor but had no oxygen requirement and a regular respiratory rate when calm. Further history revealed he had progressive dyspnea since decannulation one month prior and was sent to the ED by his radiation oncologist during a routine visit. He had a history of sleep apnea and chronic renal insufficiency. Primary assessment revealed that he had trismus, a well healed free flap in the lateral oropharynx, and a Mallampati grade of 3. He had a large neck and a nearly healed tracheostomy site with a small amount of granulation tissue in the residual tract.

The patient was notified of the need for NPL evaluation and that topical anesthesia would be avoided due to the risk of virus aerosolization and of worsening his airway. He became more anxious and had increasingly loud stridor and tachypnea. A disposable bronchoscope, tracheostomy set, Kerrison rongeurs, endotracheal tubes of varying size, and a videolaryngoscope were opened at bedside. The head and neck senior resident, anesthesia attending, and a respiratory therapist donned full PPE and prepared for intubation or tracheostomy in the ED negative pressure room in case of decompensation.

The patient was preoxygenated in case a rapid sequence induction was needed for oral intubation. Fiberoptic NPL revealed mild laryngeal edema and normal vocal cord mobility, thus suggesting a subglottic or tracheal source of obstruction. The patient tolerated the procedure well, remained stable, and was weaned back to room air. Despite the potential need for revision tracheostomy to manage the patient's presumed infraglottic airway obstruction, it was determined that it would be best to avoid further intervention until COVID-19 testing resulted and, if possible, a CT chest could be performed. CT chest would be helpful in looking for COVID lesions and also to assess the trachea but was deferred pending COVID testing. Due to limited availability for COVID testing, all of the above steps were needed to provide a "golden ticket" to get the fastest COVID testing possible at that time. Even though the patient was not febrile, we felt that it was important because of the need for PPE, location and timing of the intervention.

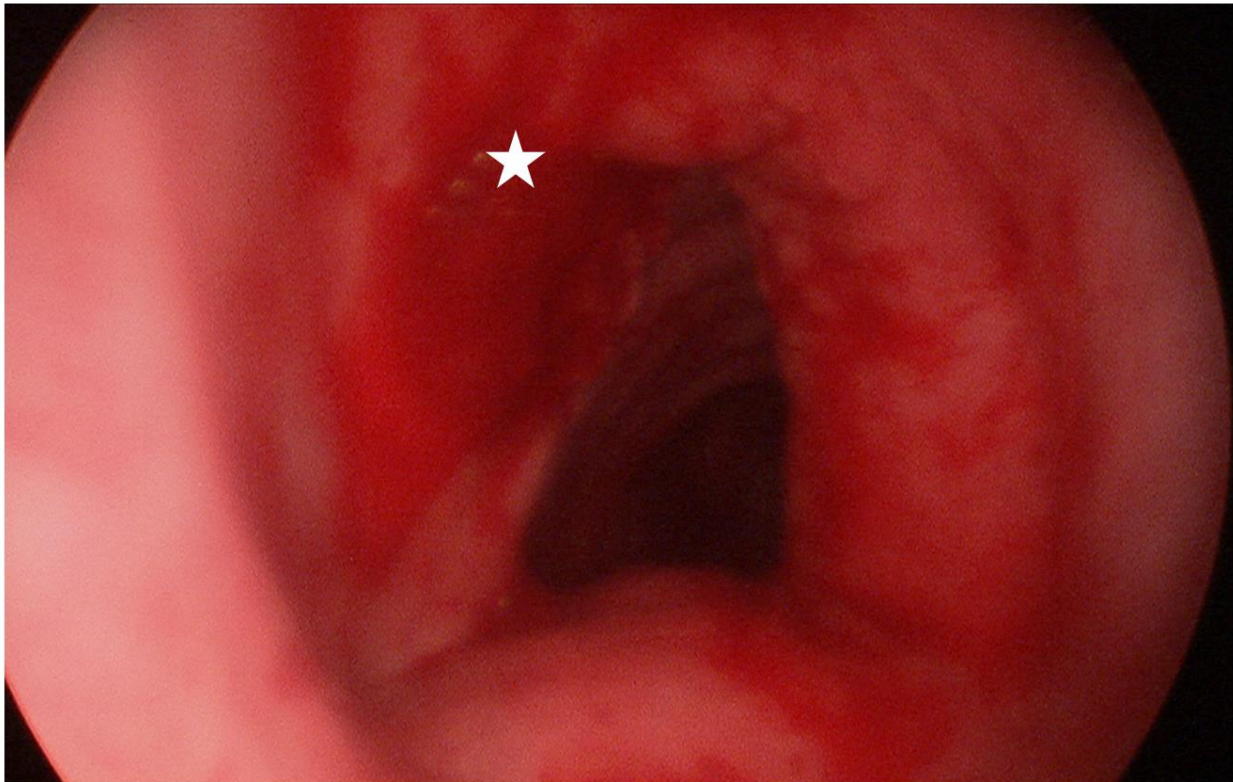
The patient was instructed to again don his mask, and he was transferred to a negative pressure room in the surgical ICU where the airway equipment was again placed at bedside. Eventually, COVID-19 testing resulted and was negative. A chest CT was obtained without contrast (due to the patient's history of renal insufficiency) and revealed multiple pulmonary metastases, a subcarinal mass (likely nodal), slight narrowing of the subglottis, and a mass in the trachea near the prior tracheostomy site, felt to be most consistent with a granuloma (**Figure 1**).



The patient remained relatively stable but was in need of airway intervention. Of note, the patient was strongly opposed to tracheostomy and almost refused to proceed, as we could not guarantee that we could safely manage his airway without a tracheostomy, nor could we guarantee safe decannulation given his prognosis. The patient was given the option of leaving AMA or choosing hospice but ultimately agreed to proceed with surgery.

Given the negative COVID test, clinical picture with absence of fever, and the likely structural source of airway distress on imaging, we decided that the patient could be taken to the operating room without the need for a negative pressure room or PAPRs. Per current hospital guidelines for aerosolizing procedures (even in presumed COVID-negative patients), all staff wore N-95 masks, face shields, gowns and gloves. Our thoracic anesthesiologist (EAO) believed he could likely intubate the patient orally, and we all agreed that awake tracheostomy or awake fiberoptic intubation would be difficult due to the tracheal lesion and the patient's anxiety. We prepared for rigid and flexible bronchoscopy as well as possible emergent tracheostomy but proceeded with a rapid sequence induction using videolaryngoscopy. The anesthesiologist had a grade I Cormack and Lehane view with the C-Mac videolaryngoscope and was able to pass an 8.0 endotracheal tube (ETT) through the glottis. Once ventilation was confirmed, we passed a flexible bronchoscope through the ETT and visualized the

tracheal lesion. We were then able to carefully pass the tube over the bronchoscope beyond the mass as it was soft. The table was turned 90 degrees and the patient suspended for telescopic laryngoscopy with an excellent view using a Lindholm laryngoscope. Ventilation was held, the ETT cuff was deflated, and the tube was withdrawn, revealing a pedunculated, friable mass. The mass was removed with upbiting cupped forceps and sent to pathology (**Figure 2**). Bleeding was controlled with topical oxymetazoline cottonoids. With the airway now clear and the patient now known to be an easy intubation via direct laryngoscopy, the decision was made to extubate the patient. The patient had immediate resolution of stridor and dyspnea and was discharged the following day. Pathology of the tracheal mass revealed carcinoma with similar appearance to his tonsil cancer, strongly suggesting metastatic disease involving the anterior tracheal wall.



DISCUSSION

This case illustrates the new challenges presented by the COVID-19 (SARS CoV-2) pandemic and brings into focus numerous challenges that are being evaluated by Otolaryngologist-Head and Neck Surgeons and multidisciplinary airway teams across the globe. Numerous institutional and specialty society guidelines have been developed in the United States as well as in Europe and Asia.¹⁻⁸

While the scenario in this case would likely otherwise have been relatively straightforward, the fact that the patient was considered a PUI complicated every step of his evaluation and management. First was the decision of who would perform primary assessment, as we have determined that more senior level responses to such consultations are needed. This prompted a discussion including faculty about whether to do NPL, which would ordinarily be performed by a resident (with topical anesthesia as needed) prior to involving the rest of the team. Second, in determining what PPE was needed for primary assessment

and NPL, it became apparent that things might progress, so we activated our ARR system. This type of system brings key personnel and equipment to the bedside during an airway emergency or for intubation in a difficult airway, but may also be used to allow for planning discussions during nonemergent but “metastable” situations that are at risk of rapid escalation.^{9,10} In this case, due to “social distancing” practices, the team consultation generated by the ARR was with six feet distance maintained among the team members.

Airway assessment by NPL was needed to allow us to get COVID testing due to a shortage of testing at the time of this scenario. In addition, it provided vital information that the obstruction was below the level of the glottis. We could not be sure the patient could be intubated with rapid sequence induction, which is the gold standard for COVID positive patients, due to his mallampati grade, trismus, challenges with upper lip bite test, and his obesity.^{11,12} Prior tracheostomy and altered anatomy from his resection and free flap were also factors making him a potentially difficult airway. In addition, even if laryngoscopy was achieved, neither oral nor nasal intubation beyond the obstruction could be guaranteed. We believed that CT scan of the chest should be performed as it would help evaluate the trachea for lesions as well as COVID lung lesions, however this required the COVID testing to be negative.^{13,14}

We have established a new set of guidelines for tracheostomy in ventilated patients in our institution but there are also unique issues associated with the postop management of patients with tracheostomy, whether they are COVID positive or negative, during this pandemic.⁵ For this patient, the psychological impact of tracheostomy was extraordinary, particularly given the possibility of needing permanent tracheostomy in the setting of likely incurable head and neck cancer. However, we felt that his complicated anatomy necessitated consent for tracheostomy if he desired airway intervention. We were also aware of and discussed potential challenges with securing necessary supplies and home nursing to manage a trach at home during the current global healthcare crisis.

Fortunately, we found that the patient had a Cormack and Lehane grade I view with both the videolaryngoscope and the Lindholm laryngoscope, was able to be ventilated both proximal and distal to the obstruction, and remained stable.¹⁵ The tracheal mass was easily removed endoscopically. We decided that this more palliative approach was in line with the patient’s current goals for airway management, particularly in light of the discovery of metastatic disease in the lungs by CT (pulmonary nodules) and the trachea on final pathology. Tracheostomy, which would have required longer admission and the risk of repeated ARR calls, was thus avoided.¹⁶ The patient was allowed to go home with the understanding that this could progress but with a plan to revisit radiation and explore options for immunotherapy pending analysis of pathology for specific mutations. Of note, while this case represents a very unusual airway complication and a poor oncologic outcome from his initial surgery, we wish to emphasize that this is an aberration from the typical treatment course of p16+ SCCA at our institution. Our institution is submitting a report of 90 cases of TORS resections and free flaps with excellent functional and oncologic outcomes (Gomez et al, manuscript in preparation).

The issues discussed in his case apply not only to tracheostomy but to all oral, nasal and pharyngolaryngeal surgery including endoscopy for cancer. Undoubtedly, management of head and neck cancer patients is a major dilemma during this pandemic. While we must protect our staff and have begun employing N-95 masks and face shields for all head and neck aerosolizing procedures, we do not yet have widespread availability of COVID testing prior to managing these patients.¹⁷⁻¹⁹ Despite that, surgery remains the best option for many head and neck cancer patients, even if it requires

tracheostomy.²⁰Without surgery, patients are faced with repeated visits to healthcare facilities for radiation and possible immune compromise associated with the addition of chemotherapy, all of which increases patients' exposure and risk of serious infection from COVID-19 during cancer treatment. This case highlights the importance of careful and collaborative decision making for the management of head and neck cancer and other "difficult airway" patients during the COVID epidemic.

Figure 1. Representative CT images demonstrating pedunculated tracheal lesion (A, C) pedicled anterolaterally on the tracheal wall just superior to the prior tracheostomy site (B). Panel D demonstrates multiple new pulmonary nodules concerning for metastases. A subcarinal mass was also seen on CT.

Figure 2. Endoscopic view of the trachea after resection of pedunculated mass demonstrating base of lesion anterolaterally on the left (labeled with a star) and mild A-frame deformity from prior tracheostomy.

References

1. Chan JYK, Wong EWY, Lam W. Practical Aspects of Otolaryngologic Clinical Services During the 2019 Novel Coronavirus Epidemic: An Experience in Hong Kong. *JAMA Otolaryngol Head Neck Surg.* 2020. [Epub ahead of print].
2. Couloigner V, Lescanne E, Klein JM, Morel N. Alerte covid-19 endoscopies et fibroscopies orl, chirurgie endonasale, tracheotomie et soins de tracheotomie. Syndicat National Des Medecins Specialises en ORL et Chirurgie Cervico-faciale. <https://www.snorl.org/category-acces-libre/alerte-covid-19-endoscopies-et-fibroscopies-orl-chirurgie-endonasale-tracheotomie-et-soins-de-tracheotomie/>. Published March 21, 2020. Accessed April 1, 2020.
3. Harrison L, Ramsden J, Winter S, Rocke J, Heward E. Guidance for Surgical Tracheostomy and Tracheostomy Tube Change during the COVID-19 Pandemic. <https://www.entuk.org/tracheostomy-guidance-during-covid-19-pandemic>. Published March 19, 2020. Accessed April 1, 2020.
4. Givi B, Schiff B, Chinn SB et al. Safety Recommendations for evaluation and surgery of the head and neck during the COVID-19 pandemic. *JAMA Otolaryngol Head Neck Surg.* 2020. [Epub ahead of print].
5. Chao TC, Braslow BM, Martin ND, et al. Tracheotomy in ventilated patients with COVID-19: Guidelines from the COVID-19 Tracheotomy Task Force, a Working Group of the Airway Safety Committee of the University of Pennsylvania Health System. *Ann Surg.* 2020. [In press].
6. Vukkadala N, Qian ZJ, Holsinger FC, Patel ZM, Rosenthal E. COVID-19 and the otolaryngologist - preliminary evidence-based review. *Laryngoscope.* 2020. [Epub ahead of print].
7. Guidance for ENT surgeons during the COVID-19 pandemic. <http://www.asohns.org.au/about-us/news-and-announcements/latest-news?article=78>. Published March 20, 2020. Accessed April 1, 2020.

8. Balakrishnan K, Schechtman S, Hogikyan ND, Teoh AYB, Brendan McGrath B, Brenner M. COVID-19 Pandemic: What every Otolaryngologist – Head & Neck Surgeon Needs to Know for Safe Airway Management. *Otolaryngol Head Neck Surg*. 2020. [In press].
9. Atkins JH, Rassekh CH, Chalian AA, Zhao J. An Airway Rapid Response System: Implementation and Utilization in a Large Academic Trauma Center. *Jt Comm J Qual Patient Saf*. 2017;43(12):653-660.
10. Hillel AT, Pandian V, Mark LJ, et al. A novel role for otolaryngologists in the multidisciplinary Difficult Airway Response Team. *Laryngoscope*. 2015;125:640-644.
11. Zuo MZ, Huang YG, Ma WH, et al. Expert Recommendations for Tracheal Intubation in Critically ill Patients with Noval Coronavirus Disease 2019. *Chin Med Sci J*. 2020. [Epub ahead of print].
12. Richa F, Chalhoub V, Gebrayel WB, El-Hage C, El Jamal, Yazbeck P. Upper lip bite test versus Modified Mallampati classification in predicting difficult laryngoscopy and/or intubation among morbidly obese patients. *J Clin Anesth*. 2020;63:109761.
13. Li Y, Peng A, Yang X, Xiao Z, Wu W, Wang Q. Clinical manifestation and management of primary malignant tumors of the cervical trachea. *Eur Arch Otorhinolaryngol*. 2014;271(2):225-35.
14. Li Y, Xia L. Coronavirus Disease 2019 (COVID-19): Role of Chest CT in Diagnosis and Management. *AJR Am J Roentgenol*. 2020:1-7. [Epub ahead of print].
15. Cormack RS, Lehane J. Difficult tracheal intubation in obstetrics. *Anaesthesia*. 1984; 39:1105-1111.
16. Rassekh CH, Zhao J, Martin ND, Chalian AA, Atkins JH. Tracheostomy Complications as a Trigger for an Airway Rapid Response: Analysis and Quality Improvement Considerations. *Otolaryngol Head Neck Surg*. 2015 Dec;153(6):921-6.
17. Chen WQ, Ling WH, Lu CY, et al. Which preventive measures might protect health care workers from SARS?. *BMC Public Health*. 2009;9:81.
18. Tran K, Cimon K, Severn M, Pessoa-silva CL, Conly J. Aerosol generating procedures and risk of transmission of acute respiratory infections to healthcare workers: a systematic review. *PLoS ONE*. 2012;7(4):e35797.
19. Wang X, Pan Z, Cheng Z. Association between 2019-nCoV transmission and N95 respirator use. *J Hosp Infect*. 2020. [Epub ahead of print].
20. Hatten KM, Brody RM, Weinstein GS, et al. Defining the Role of Free Flaps for Transoral Robotic Surgery. *Ann Plast Surg*. 2018;80(1):45-49.